

## EVALUATION OF THE ANTERIOR STOMACH IN TERM OF FOREIGN BODIES IN CATTLE

Mehmet Cengiz Han<sup>1\*</sup>, Aydın Saglayan<sup>1</sup>, Murat Tanrısever<sup>1</sup>, Eren Polat<sup>1</sup>

<sup>1</sup>Firat University, Faculty of Veterinary Medicine, Department of Surgery, Elazığ, Turkey

**Abstract.** In this study, it was aimed to assess the cattle slaughtered in Elazığ province within one year in terms of removing the foreign objects from their rumen and reticulum. As a result of the examinations after the slaughter, foreign objects at various types and dimensions were detected at the stomodeums 6138 (23,3%) of total 26.303 animals that were slaughtered. It was detected that 1876 (30,56%) of these objects detected at these animals stung or floating at rumen and reticulum and 4262 of these detected objects (69,44%) were not stung or floating. It was concluded that 4247 of these animals (69,1%) whose rumen and reticulum foreign bodies were detected was cow; 1891 of these animals (30,9%) was feeder cattle; and therefore risk of being caught by RPT disease of the animals fed at meadow conditions' may be higher compared to the animals that are subjected to house feeding.

**Keywords:** *cattle, rumen, reticulum, foreign body.*

**Corresponding Author:** *Assoc. Prof. Mehmet Cengiz Han, Firat University, Faculty of Veterinary Medicine, Department of Surgery, Elazığ, Turkey, Tel: +90-424-2370000 - 3864, e-mail: [mcengizhan@firat.edu.tr](mailto:mcengizhan@firat.edu.tr)*

**Manuscript received:** 15 March 2017

### 1. Introduction

It is known that the digestive system diseases developed at the cattle depending on swallowing foreign bodies lead to big economical losses in the milk cattle rising sector [2]. Among these, reticulo peritonitis traumatica (RPT) is one of the most important digestive system disease in Turkey and all around the world [4, 11, 13, 15, 17, 19]. According to statistical data, it was notified that the prevalence of the foreign bodies in the cattle was 94% in Germany, 80% in Switzerland, 95% in England, 75% in USA and 95% in Turkey [11].

Reticulo peritonitis traumatica is a digestive system disease that is developed a result of driller or stinging metallic foreign body perforation to the reticulum wall of the cattle and that leads to so many complications [3, 4, 7, 16, 18, 21]. Since the cattle are gourmand animals, they take sharp objects such as wires, nails, tin, iron parts and needles along with the feeds. Also some factors has a role such as that tongue and taste sensitivity of these animals are underdeveloped, their papilla on the tongue is backward, esophagus of them is wide and their reticulum has a honeycombed structure, the feeds are swollen at big masses, the chewing process is completed in a short period, their salivation are abundant, the wires are not well picked out of the herb and fodder bales, the objects such as stitching and needles are left at the places where animals may easily access in the cowsheds, the cotters are not well cleaned after the repairs

done in the cowsheds, hunger sense, the feeds that are poor in terms of phosphorus and protein are given, energy and mineral needs are increased at the periods such as pregnancy and lactation, being fed in the places closed to garbage dumps and construction lands. It was notified that the cases at which these taken foreign objects increase the abdomen volume such as tympany of rumen and pregnancy lead to perforation of reticulum wall with the effect of a strong contraction of reticulum muscles [2, 4, 6, 13, 18, 21, 14]. It was also stated that the perforation in the reticulum are mostly localized in the cranioventral and rarely overseen in the lesions within direction of medial and lateral. After the foreign bodies are penetrated into the serous tissue, they may lead to peritonitis at various degrees with the effect of the micro flora. The hepatic abscess, vagal neuritis, traumatic splenitis, pericarditis, mediastinitis, pleuritis and pneumonia are among complications of the disease [7-9, 18, 20, 22]. It was stated that RPT is widely seen at dairy cattle and lesser at anguses and rarely at sheep and goats [1, 10, 13, 15, 21].

There may be also blunt objects and sand in the rumen and reticulum of the cattle as well as the foreign bodies forming conglobates such as wood, bags, rags, plastic bags, amniotic membrane, binding ropes, twine, synthetic fibers and hairs expect for the stinging foreign bodies. It is known that the high density ones among these foreign bodies that are not stung the ventral reticulum and the low density ones are in the rumen as a floating. As densities of the sand and blunt objects, bezoar or conglobates are high, they gather in the rumen and reticulum ventral and as they form a weight here, and they may affect the reticulorumen movements. Other foreign bodies whose densities are lower may sometimes lead to mechanical obstructions at the passageways (cardia, ostium, reticuli-omasii, pylorus) [5, 12, 16].

It was stated that especially due to careless of the care personnel, the bale or packthreads taken by the animals form balls or conglobates and these objects may reach up to 30 kg or a higher weight. It was also notified that these balls or conglobates may lead to volume decrease and therefore the animals are not able to take enough feed as they lead to saturation sense at the animals and therefore may cause to efficiency decrease, losing weight and secondary ketosis [16, 12].

In this study, it was aimed to assess the cattle slaughtered in Elazığ province during one year in terms of removing the foreign objects from the rumen and reticulum.

## **2. Material and method**

A total of 26.303 cattle were inspected after slaughtering in the abattoir of Elazığ province during the study. The cattle were classified in accordance with their breeds, ages and sexes before the slaughter. In the post-mortem examination, their rumen and reticuli were carefully examined and then adherences at the reticulum wall and other complicated conditions were detected and photographed. After separating from omasum and abomasum, an incision at 10 cm length was performed to the rumen. After the contents taken at incision space, were examined in terms of their consistency, they were observantly discharged and then the

foreign bodies in the rumen that were stung or not stung were taken and taken under record. The rumen was directly entered without making an injection to the reticulum and the foreign bodies that were stung or not stung were recorded.

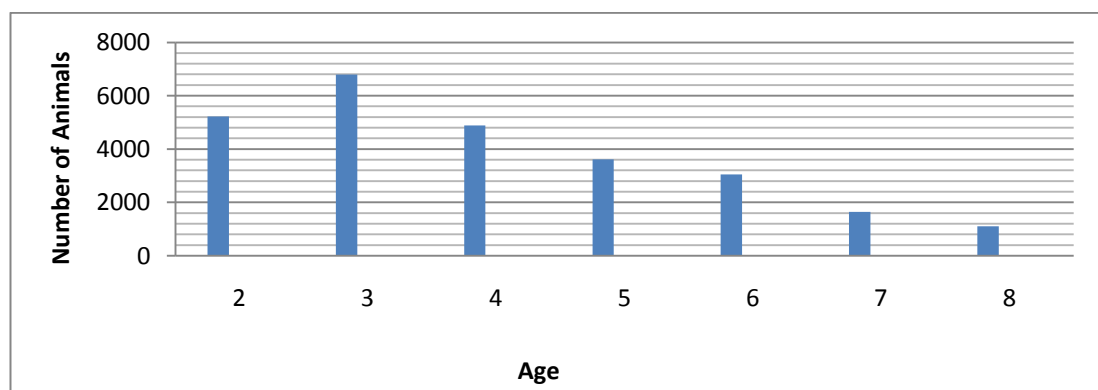
### 3. Result

The data concerning to classification of the animals in the study in terms of breed, sex and age and their examination in terms of foreign body was given at Table-1, Table-2 and Table-3.

**Table 1.** Distribution of the examined animals in accordance with breed, sex and whether a foreign body was detected or not.

Breed	Sex	Detected a Metallic Foreign Body	Not Detected a Metallic Foreign Body	Total Amount
Brown Swiss	Female	1953	825	2778
	Male	2561	807	3368
Holstein	Female	2133	739	2872
	Male	2648	517	3165
Simmental	Female	2315	749	3064
	Male	2884	567	3451
Native Black	Female	2252	632	2882
Eastern Anatolian Red	Female	1811	753	2564
Southern Anatolian Red	Female	1608	549	2157
<b>TOTAL</b>		20.165	6138	26.303

**Table 2.** Graphic of the assessed animals according to their ages (Animal-Age)

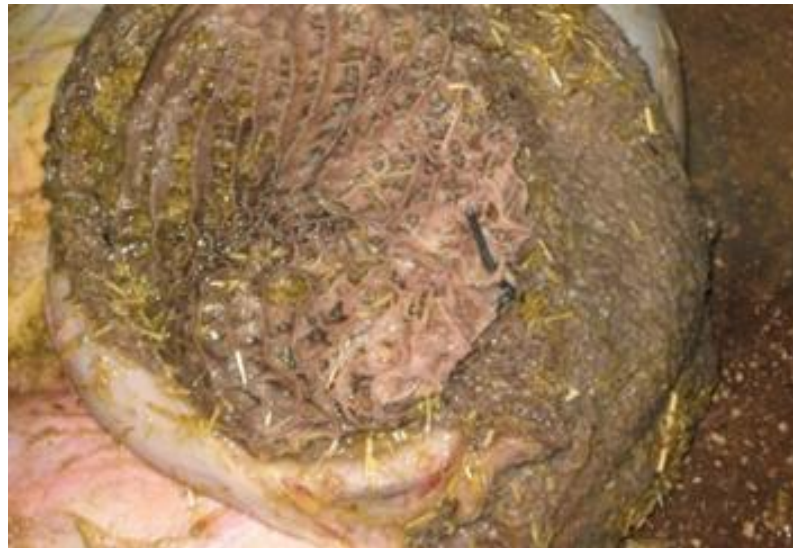

With reference the data given at Table-1, it is seen that 16.319 of 26.303 animals brought to the slaughterhouse were female and 9984 of these animals were male;

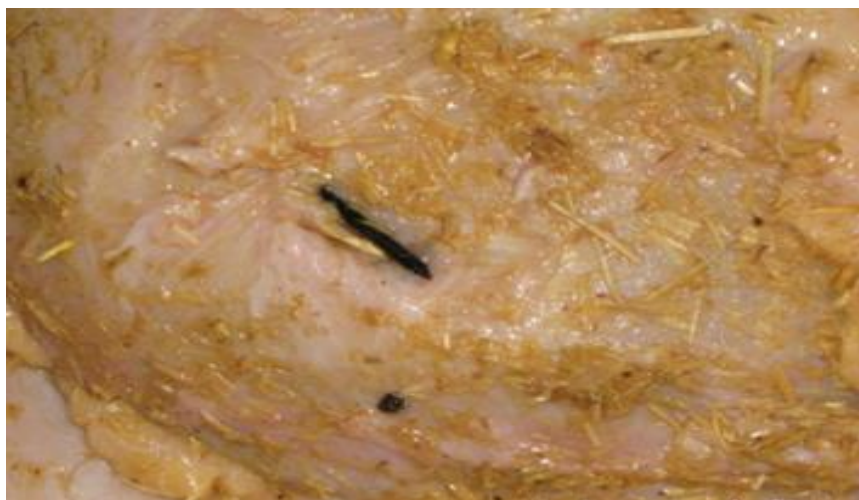6515 of these animals were Simmental, 6146 of these animals were Swiss Brown, 6037 of these animals were Holstein, 2884 of these animals were Native Black, 2564 of these animals were Eastern Anatolian Red and 2157 of these animals were Southern Anatolian Red.

**Table 3.** Distribution of metallic foreign bodies that were stung and not stung at the examined animals.

Types of the Metallic Foreign Bodies	Animal Number (n)	Percentage (%)
The ones that were stinging	5440	88,61
The ones that were both stinging and blunt	464	7,54
The ones that were blunt	64	1,03
Magnet	170	2,76



**Figure 1.** Appearance of a nail that stung at the reticulum.



**Figure 2.** Outward appearance of a nail that perforated to the reticulum wall.

#### 4. Results and discussion

In this study at which the animals slaughtered at the slaughterhouses in Elazığ within one year were assessed in terms of the foreign body removed from their rumen and reticulum, the assessment of slaughtered animals were done in terms of sex, breed and age. A total of 26.303 cattle was slaughtered during the study and 23,37% of the cattle was Brown Swiss, 22,95% was Holstein, 24,77% was Simmental, 10,96% was Native Black, 9,75% was Eastern Anatolian Red (EAR), 8,20% was Southern Anatolian Red.

It was recorded that 62,05% of slaughtered animals were female and 37,95% were male. Most of the animals that were slaughtered at their 2 and 3 ages were formed by male and this situation is supposed to be resulted from the animals at these ages are thought as butchery cattle. It was concluded that female formed most of the animals slaughtered at 5, 6, 7 and 8 ages and reason of that was efficiency losses depending on age progression of the relevant animals.

Stung or unstung metallic foreign bodies that were recorded in the post-mortem examination were assessed in accordance with their animal amounts. According to that, wire and wire parts were detected at 1944 of slaughtered animals (31,67%), nail and nail parts were detected at 1678 of slaughtered animals (27,33%), wire and nail parts were detected at 1649 of slaughtered animals (26,86), coins, wire and nail parts were detected at 215 of slaughtered animals (3,505), magnet was detected at 170 of slaughtered animals (2,76%), needle and injector tip was detected at 169 of slaughtered animals (2,75%), nail and money were detected at 116 of slaughtered animals (1,88%), wire and coins were detected at 91 of slaughtered animals (1,48%), name bracelet and similar accessories were detected at 64 of slaughtered animals (1,03%), ring and wire parts were detected at 42 of slaughtered animals (0,68%). It was stated that animal amount at which a foreign body was detected was 6138 (23,3%) and the amount of the animals at which a stung foreign body was detected was 1876 (30.56%) and animal amount at which an unstung or floating foreign body was detected was 4262 (69.44%). Gonenci and Yıldırım (2007) examined 2000 cattle and in the post-mortem examination, nail at the rate of 28,8% and wire parts at the rate of 26,8% were detected at the slaughtered animals. It was detected that the rates gained in this study were closed to these values (wire and sire parts 3167%; nail and nail parts 27,33%) and the most common foreign bodies were nail and wire parts. If it is thought that RPT is a disease resulted from sharp and stinging bodies [3, 4, 7, 16, 18, 21], it may be said that most of the animals at which a foreign body was detected in this study were carrying a RPT risk. On the other side, it was stated that prevalence of foreign body in the cattle is at 80-85% in different countries [11] while the prevalence was at 23,3% in the current study. The reason why this level was very low in our study was that only metallic foreign bodies were taken under record. Also unstung or floating objects such as hose parts and conglobates were seen in the slaughtered animals except for the metallic foreign bodies and when these objects are taken into consideration, it is thought that prevalence of foreign body may be increased. Also it was seen that it made taking all kinds of foreign bodies were recorded easily that the amount of the animals'



used in the similar studies [19, 11, 14] as material was low and it made taking all kinds of foreign bodies recorded hard that amount of the slaughtered animals in this study was too much.

It was seen in this study that magnet was seen at 170 of the slaughtered animals and when total animal amount (n=26.303) was taken into consideration, this amount was very low. If it is thought that the importance of animals' swallowing magnet is very high at prophylaxis of RPT, it may be said that precautions at satisfactory levels were not taken against this disease in this region.

As a conclusion, when driller and sharp foreign bodies that were recorded in the region at which study was done were taken into consideration, it was concluded that RPT risk was very high and enough precautions were not taken for the control of this disease. Also it was concluded that this study showed that RPT still reserves its popularity today and this study will set light to the incidence and prevalence studies that will be done concerning to this subject in future.

### References

1. Abo-Sheda M.N., Al-Rawashdeh O., Al-Natour M., (1991) Traumatic pericarditis in an Awassi lamb, *Br. Vet. J.*, 147, 78-81.
2. Akkoc A., (2007) Traumatic reticulopericarditis in a Saanen goat, *Turk. J. Vet. Anim. Sci.*, 31, 283-285.
3. Anderson N.U., (1980) *Veterinary Gastroenterology*, Lea Febiger, Philadelphia, U.S.A.
4. Blood D., Radostits O.M., (1989) *Veterinary Medicine*, 7th Edition, Bailliere-Tindall, London, United Kingdom.
5. Braun U., (2009) Traumatic pericarditis in cattle: clinical, radiographic and ultrasonographic findings, *Vet. J.*, 182, 176-186.
6. Button C., (1986) Diseases of the pericardium, myocardium, and endocardium, In: *Current veterinary therapy in food animal practice*, ed. Howard JL, 2nd ed W. B. Saunders Co., Philadelphia, PA, 696-698.
7. Cevik A., Timurkan N., Yılmaz F., (2010) Traumatic reticulopericarditis in a goat, *F.Ü. Sağ. Bil. Derg.*, 24, 103-105.
8. Ducharme N.G., (1983) Surgical considerations in the treatment of traumatic reticuloperitonitis, *Comp. Contin. Educ. Pract. Vet.*, 5, 213-219.
9. Ducharme N.G., (1994) Traumatic reticuloperitonitis in dairy cows, *J.A.V.M.A.*, 204, 874-887.
10. El-Sebaie A., (1994) Uncommon sequele of ingested sharp foreign bodies in goats, I- Traumatic reticuloperitonitis with suppurative hepatitis in a goat, *Ass. Vet. Med. J.*, 30, 158-161.
11. Gonenci M., Yildirim M., (2008) Investigation of foreign bodies and their complications in rumen and reticulum of the cattle brought to Iskenderun Slaughterhouse, *YYÜ Vet. Fak. Derg.*, 2, 31-36.
12. Gül Y., (2006) *Geviş Getiren Hayvanların İç Hastalıkları*, 2. Baskı, Medipres Matbaacılık, Malatya, Türkiye.
13. Hoffsis G.F., (1980) Traumatic pericarditis. In: Amstutz, H.E., (Ed.): *Bovine medicine and surgery*, American Veterinary Publishers, Santa Barbara, PA, 753-756.
14. Karademir B., Atalan G., (2003) The prevalence of traumatic reticuloperitonitis in cattle of Kars province, *Turk J. Vet. Surg.*, 9, 26-28.

15. Maddy K.T., (1954) Traumatic gastritis in sheep and goats, *J. Vet. Med. Assoc.*, 124, 124-125.
16. Schweizer T., Sydler T., Braun U., (2003) Cardiomyopathy, endocarditis valvularis thromboticans and pericarditis traumatica in cows, clinical and echocardiographical findings in three cases, *Schweiz. Arch. Tierheilkd.*, 145, 425-430.
17. Sojka J.E., White M.R., Widmer W.R., VanAlstine W.G., (1990) An unusual case of traumatic pericarditis in a cow, *J. Vet. Diagn. Invest.*, , 2, 139-142.
18. Streeter R.N., (1993) Traumatic reticuloperitonitis and its sequele, In current veterinary therapy food animal practice, W.B. Saunders Company, London, 719-722.
19. Tesfaye D., Chanie M., (2012) Study on rumen and reticulum foreign bodies in cattle slaughtered at Jimma Municipal Abattoir, *South West Ethiopia, A.E.J.S.R.*, 7, 160-167.
20. Toenniessen J.G., Losonsky J.M., (1994) Traumatic reticuloperitonitis, *Vet. Radiol. Ultrasound*, 4, 22-23.
21. Yoshida Y., (1991) Electrophoretic studies on serum proteins in cows with traumatic pericarditis, *J. Vet. Med. Sci.*, 53, 5-11.
22. Yoshida, Y., (1986) Total and differential leucocyte counts of traumatic gastritis classified under three types in dairy cows, *Jpn. J. Vet. Sci.*, 48,1215-1219.